

## Effect of Omega-3 Drug and Virgin Coconut Oil in Histopathological and Molecular Changes in Liver of Experimentally Obese Pregnant Albino Rats

Anfal Mohammed Ibrahim<sup>1</sup>, Liqaa Hussain Ali Al-Duliami<sup>2</sup> and Mohammed G. Saeed<sup>3</sup>

<sup>1</sup>Department of Biology, College of Education for Girls, University of Mosul, Mosul, IRAQ.

<sup>2</sup>Department of Biology, College of Education for Girls, University of Mosul, Mosul, IRAQ.

<sup>3</sup>Department of Pathology and Poultry Diseases, College of Veterinary Medicine, University of Mosul, Mosul, IRAQ.

<sup>1</sup>Corresponding Author: anfalalsnjry@gmail.com



www.jrasb.com || Vol. 1 No. 4 (2022): October Issue

Received: 02-09-2022

Revised: 23-09-2022

Accepted: 03-10-2022

### ABSTRACT

The study aimed to evaluate the role of omega-3 and coconut oil in the histological changes caused by obesity in the liver of pregnant obese female rats and to evaluate the molecular change by estimating the gene expression of the insulin-like growth factor-1 (IGF-1) and insulin-like growth factor binding protein (IGFBP-1) genes. The study used 50 albino female rats aging (90-110) and weighting (185-200gr). The experiment included two stages. First stage was to induce obesity by adding (45% fat) to the standard diet, except for the control group. In the second stage, female rats were left to mate and were divided into 5 groups (10 for each group) as follows: G1 was the Control group that remained on a standard diet, G2 was fed a high-fat diet only, G3 was orally dosed with Omega-3 (260 g/kg), G4 was orally dosed with coconut oil (200 mg/kg), G5 was orally dosed with both Omega 3 and coconut oil with the same doses. Animals were sacrificed on the 18<sup>th</sup> day of pregnancy. Histological examination of the G2 liver showed severe steatosis in hepatocytes, cellular swelling, and congestion in the central portal vein; lipid profile results showed a reduction in total Cholesterol, triglycerides, and LDL-C in the blood serum of groups treated with both omega3 and Coconut oil. Liver in the group treated with Omega 3 alone or with coconut oil showed the normal histological features of the liver tissue. The liver of the G4 group, treated with coconut oil, showed slight cloudy degeneration of some hepatocytes with individual necrosis of some of the others and congestion in the portal vein. Groups treated with omega-3 and coconut oil separately or together showed an increase in the gene expression of IGF-1 and IGFBP-1.

**Keywords-** Omega3, Coconut oil, Liver, Obesity, Pregnant rat, Molecular.

## I. INTRODUCTION

Obesity is the accumulation of high-fat mass in the body, exceeding the amounts required for normal body function, negatively impacting health [1]. Body Mass Index (BMI) is the easiest and most common way to classify Underweight, overweight, and obese in adults, defined as weight in kilograms divided by the square of height in meters (kg/m<sup>2</sup>) [2]. The rate of obesity among women of childbearing age has increased to about 36% in the last years; maternal obesity is associated with many risks, including repeated miscarriages and stillbirths [3]. Obesity is also associated with gestational metabolic

syndrome, inflammation, high blood pressure, heart disease, preeclampsia, and gestational diabetes [4]. Obesity also has harmful effects on the liver, as it causes fatty degeneration in the liver and a clear impairment of its functions [5].

Omega 3 consists of fatty acids that cannot be manufactured inside the body, so it is considered one of the essential fatty acids. It is very important for humans and animals as it is involved in the composition of vital body parts. Omega-3 fatty acids are polyunsaturated fatty acids Poly Unsaturated Fatty Acid (PUFA), which has more than one double bond within their structure [6]. Studies in recent years have shown that taking nutritional

supplements rich in omega 3 has anti-obesity effects, and is essential for human health as antioxidants and inflammation, so it is possible that food supplements containing omega 3 have beneficial effects during pregnancy and may contribute to reducing complex pregnancy problems. And associated diseases include cardiovascular disease, insulin resistance, gestational diabetes, and many other problems [7, 8].

Coconut oil extracted from the fruit of the Coconut is one of the edible oils rich in medium-chain saturated fatty acids and has gained great popularity in recent years. It was previously believed that it increases fat blood levels. Still, recent studies have shown positive results for this oil on the health of humans, as it was found that it contributes to protecting the heart and liver, is an antioxidant, anti-inflammatory, and lipids, and increases the feeling of satiety [9, 10].

The study aimed to evaluate the role of omega-3 and coconut oil in the histological and molecular changes caused by obesity on the liver in pregnant obese female rats.

## II. MATERIALS AND METHODS

### A- Animals

50 adult female albino rats (weighing 185-200 g) and age (90-110) days were obtained from the animal house of the College of Veterinary Medicine, University of Mosul, Iraq. The rats were housed in well-ventilated cages, and left for two weeks to acclimatize under Standard conditions of temperature, humidity, and photoperiodicity of 12 hours light and 12 hours dark. Animals were provided water and the necessary fodder daily throughout the experiment. In this study, omega-3 was obtained from AMS (AMERECA MEDIC & SCIENCE), while, Coconut oil was prepared by cold extraction method according to [11].

A standard diet was used in this study in proportions approved by (the National Research Council for Rats (NRC), 1994). The contents of the diet are soybean meal 20%, feed maize 45%, feed wheat 24%, animal protein 10%, And table salt 0.5%, and lime 0.5%) it was used in the control group (without fattening), and a high-fat diet was used for the rest of the groups by adding 45% of fat to the standard diet [12].

### B- Experimental design

The initial weights of the experimental animals were recorded. The experiment included two stages. The first stage was the induction of obesity which lasted for 14 weeks, and in which animals were fed the previously mentioned fattening ration, except for the control group (non-fattened), which was fed on the standard diet only, the weights were recorded weekly during this stage to monitor the weight, and after the fattening phase ended, the female rats mated by mixed males with the females, and the appearance of the vaginal plug was noted as a sign of the successful mating. Then the second stage (the treatment stage) started from the first day until the 18<sup>th</sup>

day of pregnancy. During the treatment period, animals continued to be fed the same high-fat diet during pregnancy, except for the control group, which was fed the standard diet before and after pregnancy. Animals were divided into five equal groups. The experiments' groups were divided into G1: the Control group (non-obese), dosed daily with distilled water, and G2, in which the female rats were fed only high-fat food. They orally dosed daily with distilled water during the pregnancy. G3: female rats were fed on a high-fat diet and orally dosed with 260 mg/kg of omega-3, according to the source [13], during pregnancy. G4: animals also depended on a high-fat diet and were given oral coconut oil, at a dose of 200 mg/kg according to the reference [11], G5: female rats were fed on a high-fat diet, with omega-3 and coconut oil oral administration at the same doses mentioned above.

### C- Blood sample collection and serum lipid profile estimation

Blood samples were collected from female rats for all experimental groups on the 18<sup>th</sup> day of pregnancy, and blood samples were obtained from eye canthus. The serum lipids were measured, which included the estimation of total Cholesterol T.C., triglycerides T.G. and high-density lipoprotein HDL using the Cobas C111 device.

### D- Histological examination

After the animals were sacrificed on the 18<sup>th</sup> day of pregnancy, specimens of liver tissues were immediately fixed in 10% buffer formalin, then treated with a conventional grade of alcohol and xylol, embedded in paraffin, and sectioned at 4-6  $\mu$  thickness. The sections were stained with Haematoxylin and Eosin (H&E) stain to study the histopathological changes [14].

### E- Molecular study (gene expression of IGF-1 and IGFBP-1):

It included three stages:

#### 1- RNA extraction:

100 mg of frozen liver samples at -80° C were used to isolate total RNA using the S.V. Total RNA Isolation System, (Promega, USA).

#### 2- Reverse transcription of RNA to cDNA:

The next step was preparing and running the First-Strand cDNA Synthesis by adding the reverse transcription reaction mix to RNA and primer mix to each reaction and incubating using a Biometra thermal cycler (Tprofessional® Basic 96, An Analytic Jena Company, Germany). The following protocol was used: Priming for 5 minutes at 25 °C. Reverse transcription at 42°C for up to 53 minutes, and R.T. inactivation for 1 minute. At 95 °C. Finally, cDNA samples were kept at -20 °C until further processing.

#### 3- Running quantitative reverse transcription polymerase chain reaction (qRT-PCR)

Quantitative reverse transcription polymerase chain reaction (qRT-PCR) was performed to analyze the gene expression of IGF-1 and IGFBP-1 using a Bioevapeak Real-Time PCR System™ Real-Time PCR System (China) and SYBR green method using

GoScript™ Reverse Transcription System. Relative gene expression was determined by relative qPCR using the comparative C.T. method (several cycles required for the fluorescent signal to cross the threshold). The RT-qPCR cycling conditions were an initial denaturation for three minutes at 95 C, followed by 35 cycles of annealing at 95

°C for one minute, and 60 °C for one minute, and extension at 72 °C for one minute. The Bioevapeak Real-Time qPCR Software (PCR-Q96-5) V. 2022 was run to analyze the relative quantitative PCR, and values obtained from each sample were normalized to β actin expression (housekeeping gene).

MRNAs	Sequences
<i>B actin</i>	F 5'-TTG CCC TAG ACT TCG AGC AA-3'
	R 5'-AGA CTT ACA GTG TGG CCT CC-3'
<i>IGF-1</i>	F 5'-TATGGCTCCAGCATTCCGGA-3'
	R 5'-AGGCGACGTTCCGATGTTT-3'
<i>IGFBP-1</i>	F 5'-GGTTCTCAGCATGAAGAGGCA-3'
	F 5'-TGAGGTGGAAGCTATCCAGCA-3'

### III. RESULTS AND DISCUSSION

#### A. lipid profile

The present data indicated that total serum lipids, Cholesterol, triglycerides, and LDL-c increased

significantly in the obese group and decreased in the treated groups, especially in the group treated with both omega-3 and Coconut oil. In contrast, HDL-c levels were decreased in the obese group and increased in the treated groups, as in the table (1).

Table 1: Serum lipid profile of pregnant female

Groups	T.C.	TG	LDL	HDL
G1 (Control)	79±3.16 a	78.21±1.40 a	17.91±0.43a	45.5±1.01 a
G2	130.76±3.14 b	198.04±2.90 b	63.84±2.03b	27.34±1.31 b
G3	85.6±3.2 c	104.51±3.36 c	25.26±2 c	37.5±0.6 c
G4	94.4±2.29 d	116.05±3.25 d	40.73±1.29 d	30.45±1.35 d
G5	81.5±0.51 a	89.8±3.06 e	21.8±1.43 e	40.8±0.64 e

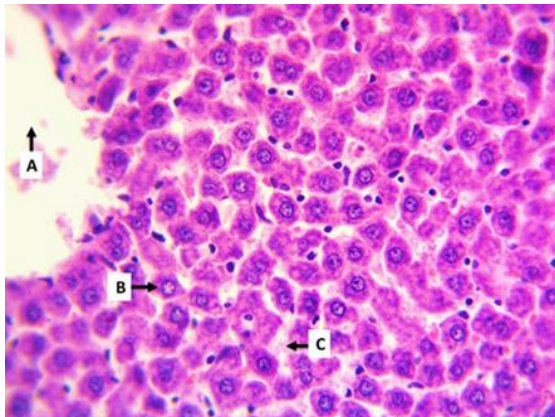
#### B. Histopathological changes in the liver

The results of microscopic examination of the liver in the pregnant female rats of the control group showed the normal histological features represented by the central vein and the hepatocytes arranged around it, which are confined by the sinusoids (Fig.1). In contrast, the liver in G2 (obese group) showed severe steatosis in hepatocytes represented by the presence of fatty droplets in the cytoplasm of hepatocyte, as well as cellular swelling and congestion in the central portal vein as in (Fig.2), this result agreed with [15], who gave high-fat diet for 8 weeks, he observed degenerative changes in hepatocytes with deposition of lipid droplets and infiltration of inflammatory cells. In a similar study by researchers [16] on a high-fat diet, they concluded the presence of necrosis and fatty degeneration of hepatocytes with infiltration of lymphocytes. [17] note the same changes in liver tissue as a result of feeding with a high-fat diet; the reason for the histological damage in the liver due to the effect of a high-fat diet, which alters the normal function of the liver, because an imbalance in the hepatocytes to get rid of excess fat and bind it with proteins to form lipoproteins, and as a result, fat accumulates inside fat cells in the form of fat droplets [18], or because of oxidative stress resulting from obesity

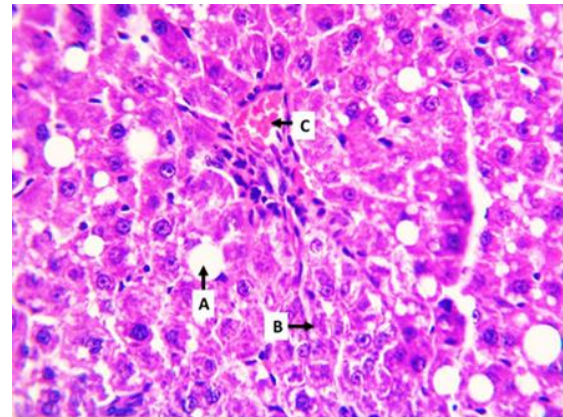
and increased formation free radicals that attack hepatocytes [19]. The Liver of G3 group treated with Omega 3 drug showed normal hepatic architecture with central vein, normal hepatocytes and sinusoids, a little vacuolar degeneration was also observed in the hepatocytes and the diameter of the sinusoids returned to their normal size (Fig.3) this result agrees with the result of [13] that omega-3 has a preventive and curative role in improving and reducing liver tissue damage resulting from treatment with toxic lead acetate, as the researcher [20] observed a decrease in the accumulation of hepatic fat when following a diet containing both fish oil rich in omega-3 fatty acids (Eicosapentaenoic acid EPA, Docosahexaenoic acid DHA) and coconut oil, as the omega-3 fatty acids have a down-regulation role in the expression of lipogenesis genes including the lipid transcription factor PPARG2 compared with the group fed on the high-fat diet and indicated that this transcription factor is one of the main factors for steatosis occurrence caused by over nutrition, and omega-3 is a powerful antioxidant that has the ability to attack reactive oxygen molecules. Liver of the G4 group treated with coconut oil, showed slight cloudy degeneration of some hepatocytes with individual necrosis of some of the others and congestion in the portal vein (Fig.4). This indicates

the role of coconut oil in reducing the lesions resulting from the effect of obesity, which is consistent with what was stated by the researcher [21], who concluded that coconut oil works to reduce high levels of liver enzymes when treated with a toxic dose of paracetamol and attributed the reason for this to the role of Coconut in restoring the normal position of the hepatic cell membranes that prevented the enzymes from entering the blood. The reason for stimulating the regeneration of liver

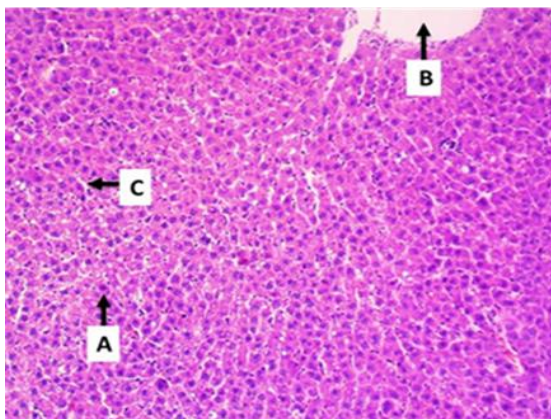
cells may be attributed to its role in promoting the formation of protein and glycoprotein or accelerating the removal and disposal of toxins. Coconut oil and the antioxidant activity that this substance possesses is the reason for the protective role of coconut oil in maintaining a healthy liver [22]. While the group treated with omega-3 and Coconut oil showed the normal histological features of the liver tissue represented by normal hepatocytes and central vein and an expansion in the sinusoids (Fig.5).



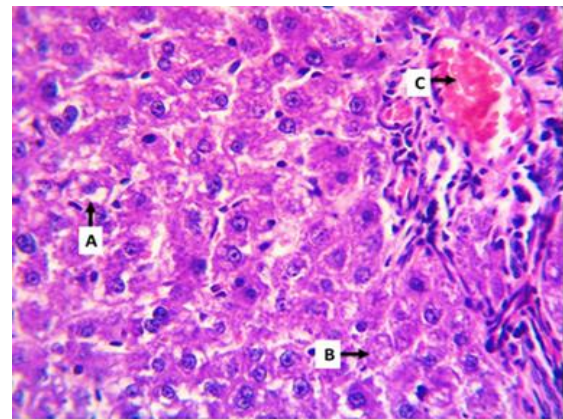
**Figure 1: G1 Central vein (A), hepatocyte (B) and sinusoids (C), H&E X400**



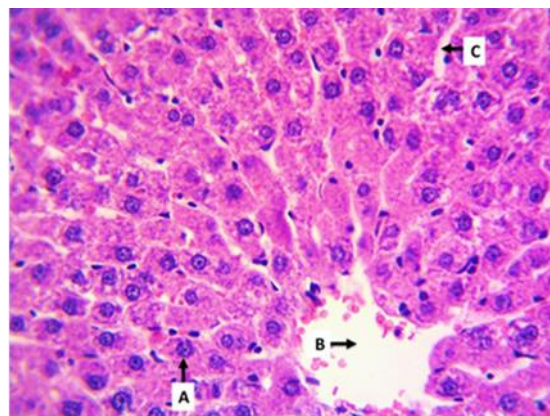
**Figure.2: G2steatosis hepatocytes (A) necrosis (B) congestion of the portal vein (C), H&E X400 X400X400 (hematoxylin and eosin stains).**



**Figure 3: G3central vein (B), hepatocytes (A), sinusoids (C), H&E X100**



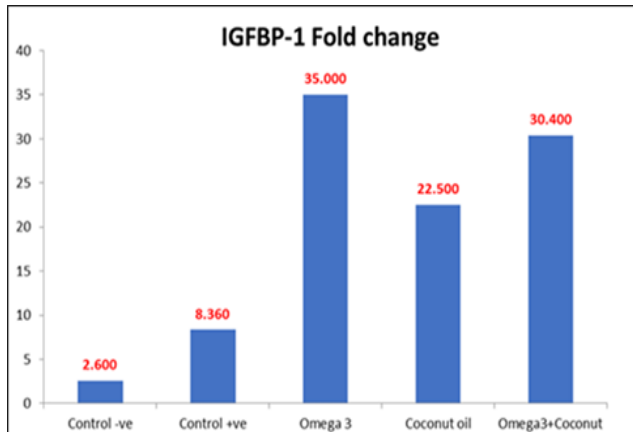
**Figure 4: G4 cloudy degeneration (A) necrosis (B) portal vein congestion (C), H&E X400**



**Figure 5: G5 hepatocytes (A), central vein (B), sinusoids (C), H&E X400**


### C. Result of Gene expression

Statistical analysis of insulin-like growth factor-1 (IGF-1) gene expression showed an increase in the number of protein folds in the omega-3 group by an average of 3.5 folds and the coconut oil group by an average of 1.3 folds, while it was in the omega-3- and coconut-oil-treated group 2.5-folds comparison with the



The results of the study showed that there was no significant change in the obese group compared with the control group in the gene expression of both IGF-1 and IGFBP-1. Giving omega-3 alone or with coconut oil led to a clear increase in the gene expression of the insulin-like hormone, while giving coconut oil alone significantly decreased the gene expression of IGF-1 compared to the obese group of animals. This is due to the role that this hormone plays in the activity of cells by affecting their growth and vitality through the positive effect of omega-3 oil and coconut oil at the cell level by reducing the fat level. IGF-1 is unstable when it is secreted and moved within the blood. Reaching its normal function in tissues is associated with the hormone that transports it, which also has a role in many pathophysiological conditions [23]. This view supports the results of the current study on the association of the gene expression level of insulin-like hormone 1 and its transporter protein, IGFBP1. The reason for the low level of lipids may be attributed to the biological activity of IGF1 closely associated with the transporter protein IGFBP1, which in turn regulates the action and activity of IGF1 and the cell response to it independently and not dependent on its level inside or outside the cell [24]. It is very clear here that IGF1 has An effective role in the balance of fats inside the cell and tissues in general through its vital role in fat metabolism and reducing the percentage of sugar loss or exit from hepatocytes and converting it to fat deposited in tissues or its high level in the blood serum, thanks to the transporter protein IGFBP1, which in turn increases the intake of fats Sugars in tissues and reduce the percentage of their loss from the liver to increase the metabolism of sugars. This opinion agrees with what the researcher [25], who explained that the role of IGF1 and IGFBP is to maintain the balance of sugars in the hepatocyte and contribute to

control group. Statistical analysis of insulin-like growth factor binding protein-1 (IGFBP1) gene expression in the mother showed an increase in the number of protein folds for IGFBP1 to 35-folds in the omega-3 group, 22.5-folds in the coconut oil group, and 30 folds in the omega-3 group with coconut oil compared with the fattening group 8.3-folds and the control group that was average 2-fold.



the metabolism of fats. Insulin-mediated metabolism, in addition to its primary role in whole-body homeostasis, glucose, and lipids, this organ is also a major site for the synthesis of insulin-like growth factor 1 (IGFI), as well as proteins IGFBPs and thus affect whole-body metabolism and growth [26] and this was demonstrated by the current study in the study of the gene expression of insulin-like growth factor and its binding protein.

## IV. CONCLUSION

The results obtained in this study was found that a high-fat diet leads to an increase in many tissue lesions, giving omega-3 and coconut oil reduced these lesions nearly to the normal situation, as well as reducing total Cholesterol, triglyceride, and LDL-C in the blood serum, especially in the group treated with both omega-3 and Coconut oil and increase the gene expression of IGF-1 and IGFBP-1.

## ACKNOWLEDGMENTS

The authors like to thank the College of veterinary medicine, and the University of Mosul in Iraq for backup the current work.

## REFERENCES

- [1] Adewoyin M., Ibrahim M., Roszaman R., Isa M., Alewi N., Rafa A. & Anuar M. (2017). Male Infertility: The Effect of Natural Antioxidants and Phytocompounds on Seminal Oxidative Stress. *Diseases*, 5(1): 9-34.
- [2] Garvey W.T., Mechanick J.I., Brett E.M., Garber A.J., Hurley D.L., Jastreboff A.M., Nadolsky K., Pessah-Pollack R. & Plodkowski R. (2016). *American*

association of clinical endocrinologists and American College of endocrinology comprehensive clinical practice guidelines for medical care of patients with obesity. *Endocrine Practice*, 22(S3): 1-203.

[3] Mahany E.B., Han X., Borges B.C., da Silveira C.S., Allen S.J., Garcia-Galiano D., Hoenerhoff M.J., Bellefontaine N.H. & Elias C.F. (2018). Obesity and High-Fat Diet Induce Distinct Changes in Placental Gene Expression and Pregnancy Outcome. *Endocrinology*, 159(4): 1718-1733.

[4] Ryckman K.K., Borowski K.S., Parikh N.I. & Saftlas A.F. (2013). Pregnancy Complications and the Risk of Metabolic Syndrome for the Offspring. *Current Cardiovascular Risk Reports*, 7(3): 217-223.

[5] Bruce K.D., Cagampang F.R., Argenton M., Zhang J., Ethirajan P.L., Burdge G.C., Bateman A.C., Clough G.F., Poston L., Hanson M.A., McConnell J.M. & Byrne C.D. (2009). Maternal high-fat feeding primes steatohepatitis in adult mice offspring, involving mitochondrial dysfunction and altered lipogenesis gene expression. *Hepatology*, 50(6): 1796-1808.

[6] Gammone M.A., Riccioni G., Parrinello G. & D'Orazio N. (2018). Omega-3 Polyunsaturated Fatty Acids: Benefits and Endpoints in Sport. *Nutrients*, 11(1): 46-61.

[7] Satokar V.V., Cutfield W.S., Cameron-Smith D. & Albert B.B. (2020). Omega-3 fats in pregnancy: could a targeted approach lead to better metabolic health for children?. *Nutrition Reviews*, 79(5): 574-584.

[8] Jones M.L., Mark P.J. & Waddell B.J. (2014). Maternal dietary omega-3 fatty acids and placental function. *Reproduction*, 147(5): R143-R152.

[9] El-Meidany W.M.R., Tayel D.I., Abd El-Maksoud M.S., Fetohy E.M. & El-Sahn. F.A. (2021). Effect of Virgin Coconut Oil Supplementation on Anthropometrical Parameters and Dietary Intake of Autistic Children. *Canadian Journal of Clinical Nutrition*, 9 (2): 33-50.

[10] Irnawati A., Erwanto Y., Lukitaningsih E., Rafi M., Fadzilah N.A., Windarsih A., Sulaiman A. & Zakaria Z. (2019). Virgin Coconut Oil: Extraction, Physicochemical Properties, Biological Activities and Its Authentication Analysis. *Food Reviews International*, 37(1): 1-21

[11] Adeyemi W.J., Olayaki L.A., Abdussalam T.A., Toriola A.P., Olowu A.B, Yakub A.J & Raji A.O. (2020). Investigation of the effects of dietary modification in experimental obesity: low dose of virgin coconut oil has a potent therapeutic value. *Biomedicine & Pharmacotherapy*, 126(1): 1-8.

[12] Hayes E.K., Lechowicz A., Petrik J.J., Storozhuk Y., Paez-Parent S., Dai Q., Samjoo I.A., Mansell M., Gruslin A., Holloway A.C., Raha S. & Reiss Irwin (2012). Adverse Fetal and Neonatal Outcomes Associated with a Life-Long High Fat Diet: Role of Altered Development of the Placental Vasculature. *PLoS ONE*, 7(3): 1-12.

[13] Abdou H.M. & Hassan M.A. (2014). Protective Role of Omega-3 Polyunsaturated Fatty Acid against Lead Acetate-Induced Toxicity in Liver and Kidney of

Female Rats. *BioMed Research International*, 2014(1): 1-11.

[14] Suvarna SK, Christopher L and Bancroft JD (2019). *Bancroft's theory and practice of histological techniques*. 8th ed, Elsevier, New York, USA.

[15] Lasker S., Rahman M.M., Parvez F., Zamila M., Miah P., Nahar K., Kabir F., Sharmin S.B., Subhan N., Ahsan G.U. & Alam M.A. (2019). High-fat diet-induced metabolic syndrome and oxidative stress in obese rats are ameliorated by yogurt supplementation. *Scientific Reports*, 9(1): 20026-20040.

[16] Khaserao S. & Somani R. (2017). Evaluation of Anti-Obesity Activity of Solasodine in High Fat Diet-Induced Obesity in Rat. *International Journal of Pharmacy and Pharmaceutical Sciences*, 9(3): 23-29.

[17] Karaçor K., Çam M., Orhan N., Coşgun E. & Demirin H. (2014). High Fatty Diet Effects on Rat Liver. *European journal of general medicine*, 11(2): 99-108.

[18] Saker S.A., Mohran H.A. & Lamfon H.A. (2011). Protective effect of ginger (*Zingibar officinals*) on Adriamycine - induced hepatotoxicity in Albino Rat. *Journal of Medicinal Plants Research*, 5(1): 133-140.

[19] Škrovánková S., Mišurcová L. & Machů L. (2012). Antioxidant activity and protecting health effects of common medicinal plants. *Advances in food and nutrition research*, 67(1): 75-139.

[20] Gimpfl M., Rozman J., Dahlhoff M., Kübeck R., Blutke A., Rathkolb B., Klingenspor M., de Angelis M.H., Öner-Sieben S., Seibt A., Roscher A.A., Wolf E. & Ensenaer R. (2017). Modification of the fatty acid composition of an obesogenic diet improves the maternal and placental metabolic environment in obese pregnant mice. *Biochimica et Biophysica Acta-Molecular Basis of Disease*, 1863(6): 1605-1614.

[21] Zakaria Z.A., Rofiee M.S., Somchit M.N., Zuraini A., Sulaiman M.R., Teh L.K., Salleh M.Z. & Long K. (2011). Hepatoprotective Activity of Dried- and Fermented-Processed Virgin Coconut Oil. *Evidence-Based Complementary and Alternative Medicine*, 2011(1): 1-8.

[22] Chattopadhyay R.R. (2003). Possible mechanism of hepatoprotective activity of *Azadirachta indica* leaf extract: part II. *Journal of Ethnopharmacol*, 89(2-3): 217-219.

[23] Clemmons D.R. (2007). Modifying IGF1 activity: an approach to treat endocrine disorders, atherosclerosis and cancer. *Nature Reviews Drug Discovery*, 6(10): 821-833.

[24] Clemmons D.R. (1997). Insulin-like growth factor binding proteins and their role in controlling IGF actions. *Cytokine & Growth Factor Reviews*, 8(1): 45-62

[25] Rajaram S., Baylink D.J. & Mohan S. (1997). Insulin-Like Growth Factor-Binding Proteins in Serum and Other Biological Fluids: Regulation and Functions. *Endocrine Reviews*, 18(6): 801-831.

[26] Postic C., Dentin R. & Girard J. (2004). Role of the liver in the control of carbohydrate and lipid homeostasis. *Diabetes & Metabolism Journal*, 30(5): 398-408.