

## Histological Assessment for the Effect of *Toxocara* spp. on the Intestine of Stray Dogs and Cats (Comparative Study)

Shurooq Hameed Majeed Alnassiri

Department of Biology, College of Education for Women, Tikrit University, IRAQ.

Corresponding Author: shurooq\_bio@tu.edu.iq



www.jrasb.com || Vol. 2 No. 6 (2023): December Issue

Received: 28-11-2023

Revised: 29-11-2023

Accepted: 30-11-2023

### ABSTRACT

The study demonstrated histological changes in stray dogs intestine infected with *Toxocara canis*, stray dogs collected from different areas in Saladin Governorate, Degeneration appeared in a number of epithelial cells of intestinal villi with desquamation in some of them, presence of many large gaps in mucosal cells lining these intestinal mucous glands with lymphocytic infiltration between the mucous glands and small lymph foci and appearance of dissociation and degeneration on smooth muscle layer of intestinal wall.

Intestinal villi of stray cats infected with *Toxocara cati*, showed degeneration and dissociation in epithelial cells lining it, with lymphocyte infiltration between mucous glands and small lymphatic foci, signs of degeneration appearing on the smooth muscle layer of intestinal wall and lymphocyte infiltration in serous layer.

The conclude of study that the intestinal tissues of dogs and cats infected with *toxocara* sp. Affected by the appearance of degeneration of some epithelial cells and desquamation of others and the presence of large gaps in the mucous cells lining these intestinal glands with the spread of lymphocytic infiltration, hyperplasia is one of the important conditions that reflects the pathological effects caused by worm infection.

**Keywords-** Histopathological changes, cats intestine, dogs intestine, *Toxocara canis*, *T. cati*.

### I. INTRODUCTION

Toxocarriasis is one of the most important zoonotic diseases caused by *Toxocara* spp. Represented by *T. canis* and *T. cati* are common in terminal hosts dogs, cats and other canidae and felidae that infect humans and other mammals that are symptomatic hosts (Radman *et al.*, 2000).

*Toxocara* adult worms live in front part of small intestine of dogs and cats, as dogs are the main terminal host of *T. canis* and cats are the main final hosts of *T. cati* while human and other mammals are transverse hosts (Radman *et al.*, 2000, Gillespi & Pearson, 2001).

*Toxocara canis* (Werner, 1782) Johnston, 1991 and *Toxocara cati* (schränk, 1788) Brumpt, 1927 are classified as Phylum: Nematoda, Class: Chromadorea, Order: Rhabditida, Family: Ascarididae (Roberts & Janovy, 2005).

There are several studies on diagnosis of worms in dogs and cats (Sultan, 1997; Al-Emara, 1999; Al-Qaisi, 2020) and the diagnosis of worms in the soil or feces of dogs and cats (Al-Kassar, 2009; Meriguetti *et al.*, 2017; Bakhshani *et al.*, 2019; Rostami *et al.*, 2020).

Cats and dogs are widely used in human groups, and they live in different environmental conditions, which makes them in direct and indirect contact with human life and other animals. The parasite does not succeed and cannot complete its life cycle depending on its capabilities alone, but rather if its own and host-related factors are available, as well as the environmental factors that dominate it and its host (Mahmoud, 2014; Bakhshani *et al.*, 2019; Rostami *et al.*, 2020).

Mccolm & Hutchison (1980), when slicing 72 stray cats in Glasgow, found that they were 33.3% infected with *T. cati*. In different areas of Amman in Jordan, Morsy *et al.* (1980) were found. By examining 78

stray cats, she had a catechia of 20.4%. In Cairo, Morsy *et al.* (1981) 57 stray cats with 35.1%.

In different areas of England, 92 Nichol *et al.* (1981) A wild cat found that it infected with *T. cati* worms by 53.3%. In Sweden, 100 person (1982) examined a cat and found it to have a 47% polyposis. In northern Jordan, Ismail *et al.* (1983) Examined. 123 stunted cat was infected with *T. cati* worms by 14.6%. Moore & Ocallaghan (1985) examined the stool of 376 cats in Adelaide in southern Australia, so the infection rate of *T. cati*.

The study aimed to know the histopathological effects of intestines of stray cats and dogs infected with Toxocariasis.

## II. MATERIALS AND METHODS

### 2.1 Hunting stray cats and dogs and collecting worms

Cats were caught by gunfire and dogs by poisoning with strengien or gunshots. The dissection was carried out in the field, isolated the small intestine and examined its contents. Then the worms were collected from infected animals and washed with a physiological salt solution with pH = 7 and kept in small vials in a physiological salt solution and placed in the refrigerator at 4 ° C until needed. After diagnosing worms according to phenotypic characteristics according to (Yamaguti, 1961; Soulsby, 1982).

### 2.2 Histological Study

**A: Tissue sections:** Tissue sections of the healthy organs (control group) and sections of affected organs were selected so that they included part of lesion area with a healthy part and the section was about 1 cm in length and width.

**B: Fixation and concentration of sections:** The samples were fixed using a Bowen solution or 10% formalin solution and the samples were fixed in it for 24 hours, and gradually dried by passing it in increasing concentrations of ethyl alcohol and from it to a mixture of pure alcohol and toluene and then toluene and finally was shed with paraffin wax and buried in paper forms to Cubes of Wax (Banchroft & Stevens, 1982).

**C: Histological segmentation:** Cut the 4-5 m thick wax cubes using the Rotary microtome and transfer the strip sections to the glass slides taking into account that the strip surface is shiny down. The loaded slides were transferred to Water bath for 2-3 minutes at a temperature of 37 Finally, it was transferred to a 35-40 ° C hot plate for textile brushes (Banchroft & Stevens, 1982).

**D: Pigmentation:** Harris Haematoxylin and Eosin Yellow (Banchroft & Stevens, 1982) were used. first pigment helped stain the nucleus in blue and the second cytoplasm in pink.

Humason (1967) method was used for pigmentation as follows:

1 - Remove wax from the sections using toluene and then a descending chain of ethyl alcohol with a concentration of 100% - 30%, then washed with distilled water.

2- The slides were stained with hematoxylin for 10-15 minutes, then washed with tap water for 10 minutes.

3- The slices were stained with alcohol-eosin staining for 3-5 minutes and passed with an ascending series of 70% - 100% ethyl alcohol.

4- transferred the clips to toluene.

5- The slides were tolerated by using Canada balsam and the slides were placed on a hot plate at a temperature of 37 ° C.

## III. RESULTS AND DISCUSSION

Surface of intestinal villi of stray dog intestine infected with *Toxocara canis*, It showed degeneration in a number of epithelial cells lining it with the desquamation of other numbers with in intestinal lumen, and intestinal mucous glands have many large gaps in the mucous cells lining these glands with spread of lymphocytic infiltration between mucous glands and limited lymph foci At the bases of mucous intestine, as well as "signs of disintegration and degeneration appear on smooth muscle layer of intestinal wall and on serous layer lymphocytic infiltration (Fig. 1,2,3,4)".

Intestinal villi of stray cat infected with *Toxocara cati*, It showed degeneration and dissociation in epithelial cells lining it, spread of lymphocytic infiltration between mucous glands and small lymph focal groupings, as well as degeneration appearing on the smooth muscle layer of intestinal wall and lymphocyte infiltration appeared on serous layer (Picture 5,6,7,8) (Mahmoud, 2014) mentioned that the nematodes cause their host intestinal inflammation and the inflammation may reach to the outer layer, and is characterized by emergence of chronic inflammatory cells (lymphocytes, plasma cells, phagocytic cells) in different proportions in intestinal layers. Hyperplasia is an important condition That reflects the pathogenic effects of worms and hyperplasia represent an increase in number of cells (Soulsby, 1982).

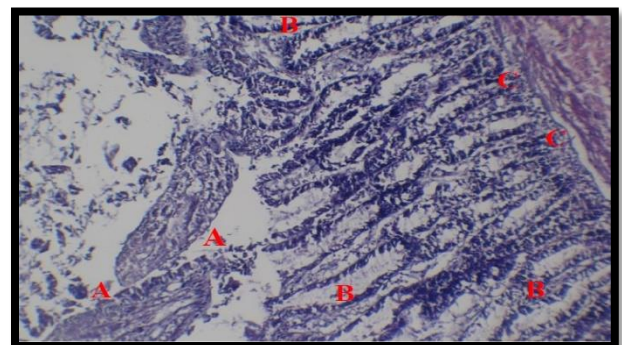


Figure1: C.S. in infected dog intestine: intestinal villi (A), clotting in some vertical cells (B), lymphocytes in core of vesicles (C), lymphocytes (D) (H & E, 100x)



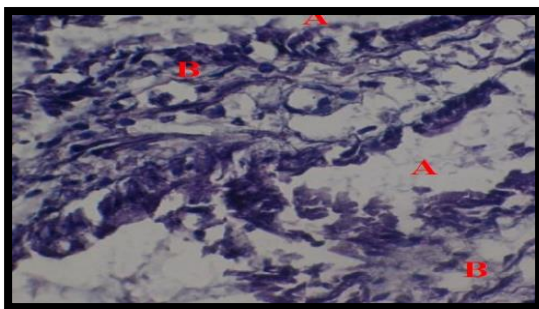


Figure2: C.S. in infected dog intestine: clotting in some vertical cells (A), lymphocytes (B) (H & E, 400x)

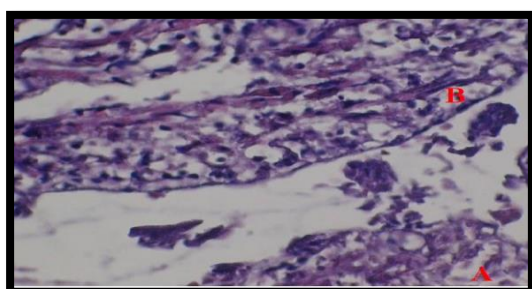


Figure 3: C.S. in infected dog intestine: clotting (A), lymphocytes (B) (H & E, 400x)

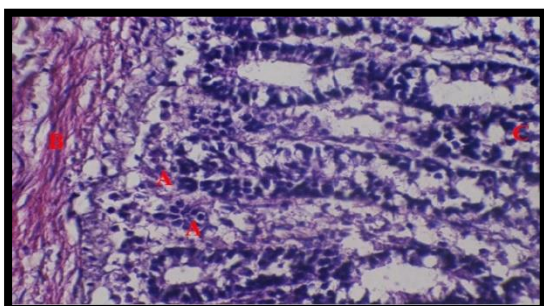


Figure 4: C.S. in infected dog intestine: intestinal villi (A), disintegration and degeneration in smooth muscle layer (B), lymphocytes in core of vesicles (C), (H & E, 400x)

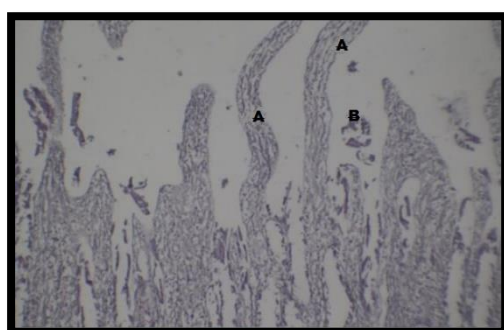


Figure 5: C.S. in infected cat intestine: intestinal villi (A), degeneration in villi (B) (H & E, 100x)

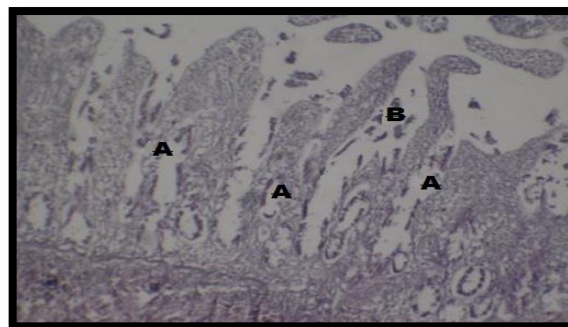


Figure 6: C.S. in infected cat intestine: intestinal villi (A), degeneration in villi (B) (H & E, 100x)

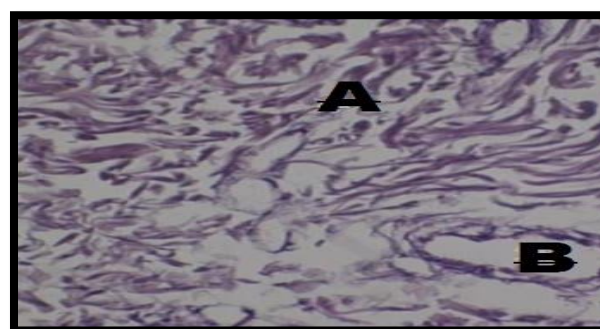


Figure 7: C.S. in infected cat intestine: lymphocytic infiltration between mucous glands (A), small lymph focal groupings (B) (H & E, 400x)

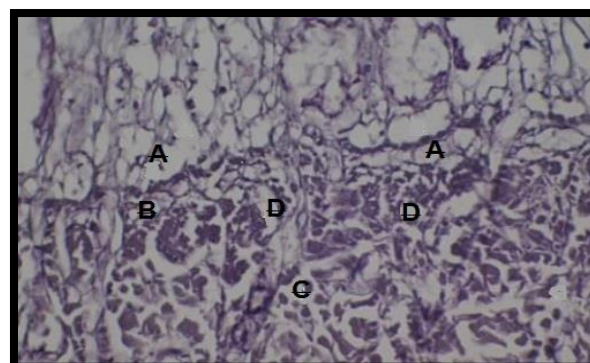


Figure 8: C.S. in infected cat intestine: degeneration and dissociation in epithelial cells (A), lymphocytic infiltration between mucous glands (B), degeneration (C), lymphocyte infiltration (D) (H & E, 100x)

## REFERENCES

- [1] Al- Bashir , N . M .& Murad , A . M . (1988) . The epidemiology of dog parasites in Baghdad ( Iraq ) I : prevalence of *Echinococcus granulosus* and other gastrointestinal helminthes in stray dogs in Baghdad . J . Biol . Sc . Res . , 19 (3) : 637 – 645 .
- [2] Al- Kassar , N . R . (2009) . Prevalence of *Toxocara* species eggs in public places and childrens play grounds

of Anassiriyah City . J . of Thin – Qar Univ ., No . 1 , Vol . 5, 38 – 46 .

[3] Al-Qaisi, E. D. (2020). Screening for Toxocariasis and its effect on Biochemical standards in some areas of Salah al-Din using Elisa and PCR techniques. M.Sc. thesis, Tikrit University, Iraq, 99pp.

[4] Al-Saeed, W. M.; Al-Dabbagh, N. y.; Mahmood, H. J. (2009). Serological study of Toxocariasis in children Mosul Province. *Medicin Journal of Babylon*, 6 (3 – 4) : 455 – 464 .

[5] Al-saffar, A. S.; Babero, B B.; Al-Dabagh, M. A. & Shaheen, A. S. (1962). The zoonosis of animal parasites in Iraq. III. The dog as a reservoir for human nematode infections, *Bull. End. Dis. Baghdad*, 4 : 1 – 17 .

[6] Bakhshani, A.; Maleki, M.; Haghparast, A.; Parandeh Shirvan, S.; Borji, H. (2019). A survey on Toxocara cati eggs on the hair of stray cats : a potential risk factor for human toxocariasis in Northeastern Iran. *Comparative Immunology, Microbiology and Infectious Diseases*, 64, 10\_13.

[7] Bancroft, J. D. & Stevens, A. (1982). Theory and practice of Histological Techniques. Zed. Churchill Livingstone, Inc., New York, pp : 662 .

[8] Gillespie, S. H.; Pearson, R. D. (2001). Principles and practice of Clinical parasitology. John Wiley & sons, London. P : 487-514

[9] Humason, G. L. (1967). Animal tissue techniques. Zed. W. H Freeman comp. Sanfrancesco. pp : 427 .

[10] Ismail, N. S.; Abdel – Hafez, S. K. & Toor, M. A. (1983). Prevalence of gastrointestinal helminthes in cats from northern Jordan. *Pak. Vet. J.*, 3 (3) : 129 – 132 .

[11] Mahmoud, A.J. (2014). The prevalence of Toxocariasis in Salahal-Din province with an immune attempt in laboratory mice Balb/c. Thesis, Tikrit Univ., Iraq.

[12] Mc colm, A. A. & Hutchison, W. M. (1980). The prevalence of intestinal helminthes in stray cats in central Scotland. *J. Helminthol.*, 54 : 255 – 257 .

[13] Meriguetti, Y.; Sihtirem, V.A.; Ramires, L.M.; da Silveira Batista, A.; da Costi Beserra, L.V.; Nuci, A.L.; de Piula Ecposte, T.M. (2017). Protective and risk factors associated with the Presence of Toxocara SPP. eggs in dog hair. *Veterinary Parasitology*, 244, 39\_43.

[14] Moore, E. & Ocallaghan, M. G. (1985). Helminths of dogs and cats determined south Australia. *Aust. Vet. J.*, 62 (6) : 198 – 199 .

[15] Morsy, T. A.; Michael, S. A. & EL – Disi, A. M. (1980). Cats as reservoir hosts of human parasites in Amman, Jordan, J. *Egypt Soc. parasitol.*, 10 (1) : 5 – 18 .

[16] Morsy, T. A.; Sadek, M. S. M. & Abdel – Hamid, M. Y. (1981). Intestinal parasites of stray cats in Cairo, Egypt. *J. Egypt. Soc. parasitol.*, 11 (2) : 331 – 345 .

[17] Nichol, S.; Ball, S. J. & Snow, K. R. (1981). Prevalence of intestinal parasites in feral cats in some urban area of England. *Vet. parasitol.*, 9 : 107 – 110 .

[18] Persson, L. (1982). Gastro – intestinal parasites of cats. 14 th Nord. Veter. Kong., Copenhagen : 6 – 9 July 1982 : 144 – 145 . (cited from *Helminthol. Abst.*, Ser. A, 53 (4) : 1177, 1984).

[19] Radman, N. E.; Archelli, S. M.; Fonroug, R. D.; Guardis, M. V. & Linzitto, R. O. (2000). Human toxocariasis. Its seroprevalence in the city of La Plata. *Memo. do Inst. Oswaldo Cruz.*, 95 : 281 – 285 .

[20] Roberts, L. S. & Janovy, J. (2005). Foundation of parasitology. 8th ed., Mc Growhill, New York. P : 431

[21] Rostami, A.; Riahi, S.M.; Hofmann, A.; Ma, G.; Wang, T.; Behniafar, H.; Taghipour, A.; Fakhri, Y.; Spotin, A.; Chang, B.C.H.; et al. (2020). Global prevalence of Toxocara infection in dogs. *Adv. Parasitol.*, 109, 561-583.

[22] Soulsby, E. J. (1982). Helminths, Arthropods And protozoa of domesticated animals. 7 th ed., Bailliere Tindall, London. p : 150– 155 .

[23] Sultan, B. E. (1997). Epidemiological study of Toxocara canis in Najaf area. Ph. D. Thesis coll. Vet. Med. Univ. Baghdad : 78 pp .

[24] Yamaguti, S. (1961). Systema Helminthum. Isted., Chancery lane, London : 679 pp .